



## INSIDE THIS ISSUE

WINTER 2012

### President's Message

Dr. Bob Havlik highlights the ASMS events in Denver and looks ahead at the many ASMS educational and membership initiatives taking shape.

### Editor's Corner

Dr. Arun Gosain talked with past recipients of the ASMS CRANIO and International Scholars and summarizes how the scholarships have affected their careers.

### Panel Discussion: Innovative Techniques in Head and Neck Reconstruction

Dr. Geoffrey Robb leads a discussion on head and neck reconstruction with his colleagues from MD Anderson Cancer Center - Matthew Hanasono, Jesse Selber, and Roman Skoracki.

### ASMS History Unique Look at the Past

Dr. Bahman Guyuron, former ASMS President looks back at the challenges faced, and ultimately surmounted, by the Society and its leadership.

### Book Review: Decision Making in Plastic Surgery

Dr. Reza Jarrahy reviews *Plastic Surgery: Clinical Problem Solving*, edited by Peter Taub and Michael Koch.

### From the Education Committee

Dr. Peter Taub outlines the many educational offerings of the ASMS coming in 2012, including new courses and publications.

### Residents and Fellows Corner

Dr. John Mesa outlines the knowledge gained by attending the ASMS courses and encourages all residents and fellows to take advantage of the wealth of information provided.

### Case Study

Christina and Peter Corceiro present a case on reconstruction of a medical cantham, orbital floor, maxillary defect.

### PESN is Live

Log in and see that the new site is all about.

### CPT Coding Corner

Dr. Greg Pearson reviews coding practices for orbital floor fractures.

### ORBIT 2011 in Ferrara, Italy

Dr. Luigi Clauser provides a comprehensive review of the events and sessions during ORBIT 2011.

### Plus photos from the 2011 Annual Meeting!

## FROM THE RESIDENT

### ASMS: Building and Growing

ASMS enters the year of 2011-2012 in a strong position from many crucial vantage points. The Society has completed a wonderful annual meeting with excellent programming and many exciting social events. The professional management has successfully transitioned from the American Society of Plastic Surgeons (ASPS) to PRRI, Inc. of Beverly, Massachusetts. The ASMS house is on a sound footing from a fiscal perspective. The New Year is filled with exciting educational offerings, both established favorites and some innovative new initiatives. These educational offerings include some exciting first time collaborations with other societies. The future for the Society is very bright indeed.

There can be no doubt that the Denver meeting was successful for ASMS. Dr. Henry Vasconez and his Program Committee put together an outstanding program kicked off by the pre-conference symposium "Solutions to Complex Craniofacial Problems". The attendance for this pre-confer-



**Robert J. Havlik, MD**  
Indiana University  
School of Medicine

(continued on page 11)

## ASMS President Captivates Audience in Denver

The following is the ASMS Presidential Address given by Steven Buchman, MD during the Opening Ceremonies of Plastic Surgery Week 2011 in Denver. An audience of more than 2,000 enjoyed Dr. Buchman's remarks.



It has been a wonderful and productive year for the American Society of Maxillofacial Surgery despite the fact that we needed to reorganize and transition the organization with a different management company. I want to thank the members of our Board for their help in achieving an excellent transition which has been quite healthy and has allowed us to reinvigorate and expand the value and contributions of the ASMS resulting in new programs and improved ways in which the society works with each other and with our membership.

(continued on page 19)

## Editor's Column: ASMS CRANIO and International Scholars

Arun Gosain, MD, University Hospital (Lakeside)

I welcome all of you to the Winter edition of the ASMS Newsletter, in which you will find highlights of the Annual Meeting, focusing on numerous areas of interest to our readership. I have invited Geoff Robb and his colleagues from M.D. Anderson to update us on innovative techniques in head and neck reconstruction. In addition to our broad spectrum of topics, we have included Steve Buchman's moving Presidential Address given in Denver and we have invited Bahman Guyuron to provide insight for the Historian's Corner.

A key program sponsored by the ASMS are fellowships for CRANIO and International Scholars. The CRANIO program has been generously funded by Doug Ousterhout without interruption since 2003 and it seeks to provide graduates of craniofacial fellowship programs with the opportunity to experience care in other centers of excellence as they establish their careers.

The International Scholars program is jointly run by the ASMS and the PSF and represents the committee with the most collaborative working relationship between the two organizations. This collaboration has eliminated administrative redundancy, streamlines the application process, and does not confuse applicants by having them apply to multiple organizations. I first became involved with the International Scholar program 20 years ago when we hosted Arun K. Singh from Lucknow, India. Today Dr. Singh is the President of the Indian Association of Plastic Surgeons, and he has encouraged many of his junior faculty and trainees to participate in this program.

To highlight the impact that these scholarship programs have had on the participants, I wish to share some of the comments from both CRANIO and International Fellows upon completion of their fellowships:

### **Arshad Muzaffar**

#### **2003 CRANIO Fellow, University of Washington, Seattle**

"Since the majority of my practice is cleft-related, this (week at NYU) was truly an enjoyable and informative week for me. Dr. Cutting shared with my many of the critical insights he has gained into cleft lip/palate repair through his vast experience. In addition, I was able to spend time in Dr. Cutting's lab, where he showed me the latest in his virtual cleft surgery project... I thank the ASMS for this fantastic opportunity. There is no better way to improve oneself as a surgeon than to observe and learn from the experts in one's field."

### **John Van Aalst**

#### **2003 CRANIO Fellow from University of North Carolina**

"The time spent was invaluable... When I indicated to hospitals/surgeons that I was traveling under the auspices of the ASMS, it was an automatic open door. The award stipend helped me to travel at a transition point in my career... when I would have been hard-pressed to find these travel funds."

### **John Giroto**

#### **2004 CRANIO Fellow, University of Rochester**

"As you all know, whether it is a car crash, cleft lip, dog bite, craniosynostosis, or birth anomaly: We are about *these* kids – kids with facial differences... Learning surgical technique, I feel, is at least bimodal. Learning and observing a skill originally in training is then replaced with personal experience – with its successes and struggles. Observing a second time, one is able to refine specifics... I would like to thank the ASMS for this opportunity to visit so many institutions and surgeons. I have altered my technique in many different areas and solidified my team management ideas so we can continue to build a center of excellence in cleft and craniofacial surgery."



### **Jugal Arneja**

#### **2005 CRANIO Fellow from Children's Hospital of Michigan**

"This award afforded me the opportunity to round out areas of clinical interest as well as gain perspective on surgical techniques and principles after having initiated practice... A comment by Dr. Linton Whitaker struck me in that he suggested that my visit now is undoubtedly of great value. However, consider visiting again in 5 years to then have the opportunity to be critical of your practice. I plan on adhering to that suggestion, and I see this fellowship as a stepping stone to future learning and critical assessment of how my practice stands compared to the 'Giants' I have had the opportunity to visit this past year."

### **Aaron Mason**

#### **2007 CRANIO Fellow, University of San Antonio**

"The fellowship further endorsed the need to continue to seek experiences that augment my current practice and expand my perspective about solutions to reconstructive problems in pediatric plastic surgery. I am grateful for the experience and would recommend it to all."

### **Craig Birgfield**

#### **2008 CRANIO Fellow, University of Washington, Seattle**

"Now that I have experienced 4 major craniofacial centers, these are my findings: Hemifacial microsomia is an important component of the care at all these centers, but still does not seem to garner the focus that cleft lip and palate and craniosynostosis does. There are over 230 cleft centers listed on the ACPA website, but none specifically listed as centers for hemifacial microsomia. Yet, the patients' needs are very similar to the needs of children with clefts. The approach to care for HFM differs from center to center in a way much as the referral pattern for other anomalies like cleft lip and palate i.e., single provider or team care... Plastic surgeons have been very successful in treating cleft lip and

(continued on page 18)

## Panel Discussion: Innovative Techniques in Head and Neck Reconstruction

*Panel Moderator: Geoffrey Robb, MD*

*Panelists: Matthew Hanasono, MD, Jesse Selber, MD, Roman Skoracki, MD*

**Dr. Robb:** I would like to introduce Dr. Roman Skoracki, Dr. Matthew Hanasono, and Dr. Jesse Selber. We're all faculty at MD Anderson Cancer Center in Houston. The ASMS readership is interested in a brief outline of the applications of the new innovative techniques mentioned in the recent ASPSP-ASMS Panel that was held on head and neck reconstruction.

There were three specific areas of reconstruction in which there is the opportunity to consistently achieve predictably superior outcomes: mandibular, mid-facial, and oropharyngeal reconstruction. So for the purpose of this initial discussion of mandibular and mid-face reconstruction, perhaps we can start by summarizing the outcomes impact of virtual planning as well as medical modeling.

**Dr. Hanasono:** Advances in computer software allow us now to take imaging data, such as from computed tomography (CT) scans, and reformat them into three-dimensional images that can be rotated and visualized in any plane. We use computer-aided design (CAD) software now especially made for modeling the craniofacial skeleton that allows us to manipulate these images. And we can also add to or subtract from them, including reconstructive hardware or reconstructive bone grafts or bone free flaps. So, in this way, we can pre-build the reconstruction before we actually do it in live surgery. As far as the medical models are concerned, we are now able to make physical three-dimensional models based on this data using specialized printers that serially lay down, layer by layer, a solid material, either a powder that can be bound by glue, or a resin that can be cured by a laser. In this way we have an actual physical model that can be sterilized and be used during surgery. And we use this model to plan our surgery, to confirm that the reconstruction is as we planned, and as a template to bend titanium hardware into the appropriate shapes during the surgery.

**Dr. Skoracki:** These technologies that Dr. Hanasono outlined are extremely powerful in that we can perform the surgery virtually on the patient's own craniofacial skeleton before we actually walk into the operating room and have to perform the surgery on the actual patient. This had led to a significant increase in reproducibility and accuracy for our surgical results. These technologies are very useful, not just for the reasons mentioned, but also as a communication tool between the resecting surgeon and the reconstructive surgeon, as well between the reconstructive surgeon and trainees, and the reconstructive surgeon and the patient.

For mandibular reconstructive patients we have found using these technologies particularly useful in the cases involving exophytic tumors, prior resection with resultant missing or distorted anatomy, or destructive processes resulting in a pathologically fractured mandible, such as in osteoradionecrosis. What all of these conditions have in common is that a reconstructive plate cannot be accurately bent on the native mandible to serve as a guide for the osteotomies. This set of tools is also useful for other patients, but we feel that in these subsets of patients, they especially facilitate surgery and allow a level of accuracy that just is not possible with the traditional methods of either temporary intra-operative external fixation or even plate bending according to space wax or acrylic models that were created using the traditional maxillofacial

prosthodontist's techniques.

**Dr. Robb:** Would you comment on any significant limitations to these approaches from any of the technology perspectives?

**Dr. Hanasono:** Yes, there are some limitations to this technology. One, that it requires time to perform preoperatively. We initially started doing this in-house with our own personnel and we had our own printer, which was a time-consuming process that involved hours of work. We have since outsourced this to a third party, but designing the reconstruction still takes approximately 30 minutes via web conference. It occasionally takes a second conference to confirm. The model themselves can be made generally overnight, and then they need to be shipped to us. It's also necessary, particularly in the cancer population in which tumors may progress in size, that the data that we send to create the virtual plan and the medical model is up to date so it requires a recent CT study. I think the largest limitation is that when the defect changes from what the anticipated plan includes, the model is no longer an exact representation of what we want to reconstruct. If we have to alter our plan intraoperatively, this takes away from the some of the benefits of this technique in terms of both accuracy and speed.

**Dr. Skoracki:** To dovetail into that, one other point is costs. That's been a real hurdle for many centers to adopt this technology because if this is to be done in house, then the cost of the printer and the subsequent maintenance costs of these three dimensional printers, as well as the cost of the software is still considerable,

though decreasing every year. Outsourcing to a third party takes care of some of that, but then there is the specific cost that is incurred for the patient and that is not currently covered by insurance companies. One solution that seems to be feasible for all parties is that this cost can be rolled into the cost of patient-specific plating that is available through the various craniofacial plating companies that have partnered with medical modeling companies to provide the CAD and the modeling services.

**Dr. Robb:** Can you comment a little about the actual techniques you utilized the medical models for during reconstructive surgery?

**Dr. Skoracki:** When we talk about models, it generally refers to a full-scale, three-dimensional replica of the patient's craniofacial skeleton. We can obtain models of the patient's native skeleton or

*There were three specific areas of reconstruction in which there is the opportunity to consistently achieve predictably superior outcomes: mandibular, mid-facial, and oropharyngeal reconstruction.*



*-Geoffrey Robb, MD*

*(continued on page 13)*



## From the Education Committee

**Peter J. Taub, M.D., Chair**  
**Mount Sinai Medical Center, New York, New York**

This year the Education Committee put on the most ambitious and perhaps most well-received preconference symposium to date. Responses from those who attended the one-day series of lectures and panel discussions were no less than spectacular. Organized by Dr. Henry Vasconez, the course provided important information regarding the current management of various structures of the head and neck as well as an in depth understanding into how to manage complex maxillofacial problems. Unfavorable results of various causes including those of iatrogenic origin were also discussed.

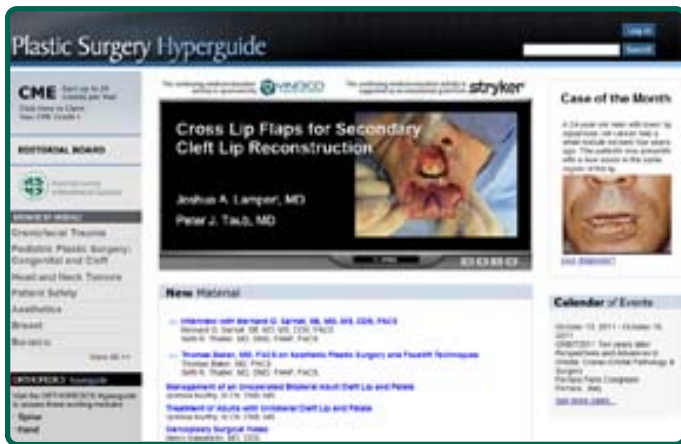Between now and next year's symposium in New Or-


leans, numerous exciting educational opportunities have been organized. These have been designed for both residents and attendings and novice and expert clinicians alike. The successful basic maxillofacial course will be hosted by Dr. William Hoffman in San Francisco in February and Dr. Pravin Patel in Chicago in August. In the Spring, an exciting new course in facial restoration and rejuvenation will be held on the campus of Louisiana State University. Also planned for the summer are two additional courses: one advanced maxillofacial course that builds on the principles of the basic course and a course in virtual surgical planning that explores novel frontiers in the work-up of patients with complex maxillofacial problems.



Two new maxillofacial textbooks are currently in production. An agreement to publish the second edition of Ferraro's Fundamentals of Maxillofacial Surgery has been reached with Springer, International and will feature new chapters from ASMS authors. Also, an atlas of craniofacial surgical procedures will be written in conjunction with the American Society of Craniofacial Surgeons.

Finally, the Plastic Surgery Hyperguide continues to add valuable information to its diverse library of lectures, video, podcasts, and unknown cases. It remains an easy access reference for all types of surgery of the head and neck, including aesthetic and patient safety topics.





### ASMS Basic Course

February 17 - 19, 2012  
 University of California San Francisco  
 San Francisco, California

▶ [Apply for the Residents and Fellow Basic Course Scholarship](#)

View Online Program

Registration

Housing

Download Course Brochure

Basic Maxillofacial Principles & Techniques: This course is a three-day program consisting of lectures and hands-on laboratory sessions. The goal of this course is to introduce the principles of maxillofacial surgery, with a unique emphasis on the topics of dental anatomy, occlusion, dental impressions, orthodontics and prosthodontics, orthognathic surgery and maxillofacial trauma.

Lectures and Labs will take place at the School of Dentistry - The Dental Center, D-4203, 707 Parnassus Avenue, San Francisco, CA 94143.

This course is supported by an educational grant from KLS Martin L.P.

## ASMS History Corner

**Bahman Guyuron, M.D., ASMS Past President**  
*University Hospitals Case Medical Center, Lyndhurst, Ohio*

When I began my term as the ASMS president, the organization was challenged by an impending economic debacle, faced an identity crisis, was threatened by political isolation, and, on the whole, the society was gravely lethargic. The financial calamity was evidenced by the withdrawal of funds from the reserve account for several consecutive years, thus reducing the ASMS assets by two thirds. Nevertheless, our Board was not daunted by these adversities. We were ready to set sail on this stormy course.

We selected "enthusiasm" as our theme considering the words of Ralph Waldo Emerson, "Nothing great was ever achieved without enthusiasm". Invigorated by these taxing issues, our Board went to work. The number one priority was to provide financial stability to the society. This goal was accomplished by increasing our revenues and reducing our expenditures. We were able to secure record corporate support in a very difficult economic milieu. How true appeared the statement by John Collins: "In prosperity our friends know us; in adversity we know our friends". One major change that we implemented was the procurement of stronger support for the ASMS Basic Course by Synthes and KLS. This was a pivotal change for ASMS and its positive financial impact has been enduring over the last 9 years. A culmination of this corporate support and the implementation of cost saving measures resulted in the return of some funds to the reserve account for the first time in many years.

This fortified fiscal stand was very encouraging but we were not content and we were steadfast in our quest for longstanding financial stability. This objective was accomplished through an ambitious membership campaign. We followed the advice of Frank Scully, "Why not go out on a

limb? Isn't that where the fruit is?" when we set an audacious goal of inducting 60 new members during this meeting. We enlisted the aid of all of our Society leaders in this endeavor. Ultimately, we exceeded this goal, increasing our membership by a record 20%.

Through John Persing's strategic initiative, we reached many sound conclusions. The most important and immediate one was the elimination of identity confusion. With a new and concisely defined mission, we clearly delineated who we were, what we wanted to achieve, and how we wanted to achieve it.

The final significant accomplishment was the improvement of our relationship with our sister societies. We demonstrated our gratefulness to the ASPS and PSEF leaders for the inclusive way in which they had embraced ASMS. We also expressed our desire to fortify our relationship with the other societies such as ASAPS. We conveyed our firm conviction that competition and menace within the specialty was not our aim. On the contrary, standing united seemed absolutely essential give the competitive environment. Providentially, the plastic surgery organizations embraced our suggestion and relationships vastly improved.

Undoubtedly, a cohesive front strengthened the specialty, benefited our patients and members alike, and sent a strong message to our competitors that we will remain unrivaled. The robust organization that we created has continued to benefit from subsequent strong leadership and I am thrilled to see ASMS unshaken over the last 9 years in spite of multiple challenges it has faced in recent years.



### ADMINISTRATIVE OFFICES & CONTACTS:

500 Cummings Center, Suite 4550

Beverly, MA 01915

Phone: (978) 927-8330 / Fax: (978) 524-8890

Email: [admin@maxface.org](mailto:admin@maxface.org) / [www.maxface.org](http://www.maxface.org)

Stanley Alger, Executive Director

Lorraine O'Grady, Administrative Director

E.J. Weldon, Director of Meetings

Visit [www.maxface.org](http://www.maxface.org)

## Residents and Fellows Corner: ASMS Sponsored Educational Opportunities

John Mesa, MD

University of Michigan, Ann Arbor, Michigan

One of the main goals of the American Society of Maxillofacial Courses is provide education to its members as well as candidate members like medical students, residents, fellows and graduated plastic surgeons. Throughout the year, the ASMS provides a great variety of courses that fit the educational needs of its participants.

The Basic ASMS Course is our 'start up' course that focuses on the introduction and teaching of the basic principles and techniques of Maxillofacial Surgery. The course is designed to be attended by junior plastic surgery residents and medical students, but senior residents are also welcome. The course is given several times per year and is held in major cities like Chicago, Philadelphia, Miami and San Francisco. Participants are given instructional lectures that follow with a hands-on laboratory practice experience. Course topics include dental anatomy, facial fractures, and orthognatic surgery. The laboratory part focuses on obtaining dental impressions, creating dental models and occlusal dental splints, necessary for adequate management of maxillofacial trauma and performance of orthognatic surgery. Additionally, participants are exposed to the maxillofacial osteosynthesis plating system, drill equipment, and different techniques of maxillofacial rigid fixation. This course is the 'foundation' of maxillofacial trauma management by plastic surgery residents.

The ASMS Advanced Maxillofacial Course as its name states, is an advanced course where the basic knowledge of maxillofacial surgery is exercised in cadaver dissections. This course is designed to be attended by senior plastic surgery residents, craniofacial surgery fellows, and practicing plastic surgeons interested in refreshing his/her knowledge and skills in maxillofacial surgical techniques. Different to the basic course, the Advance Maxillofacial course incorporates the use of fresh cadaver dissections to fully teach the principles and techniques of maxillofacial surgery in a more 'realistic' clinical scenario. Treatment of mandibular fractures, performance of othognatic surgery (LeFort I osteotomy and

***As you can see, the ASMS provides a great number of excellent educational courses for its members and candidate members. Please don't forget to check the ASMS website ([www.maxface.org](http://www.maxface.org)) to check for upcoming educational courses.***

movements, BSSO, genioplasty) as well as placement of osteointegrated implants for oral restoration and rehabilitation are though on cadavers. This is a unique learning opportunity for the improvement of maxillofacial surgical techniques. Starting next year, this course will be given in combi-

nation with the American Society of Craniofacial Surgery.

The ASMS Cleft Course is another educational course that focuses in the management of cleft lip and palate patients treated on overseas missions. This course usually follows the end of the ASMS basic maxillofacial course, and is aimed at plastic surgery residents, fellows and practicing plastic surgeons interested in performing cleft care outside the US in a mission trip. Taking a multidisciplinary approach that includes anesthesiologists, nurses, neurosurgeons, etc., the course discusses all the challenges regarding the perioperative medical and surgical management of cleft patients in an underdeveloped environment. Since cleft care can be challenging while overseas, this course allows the attendees to be better prepared to have a smooth and truly enjoyable surgical cleft care experience.

The ASMS Pre-symposium at ASPS, a day course that precedes the beginning of the ASPS annual meeting, is another educational course that focuses on different topics of maxillofacial surgery every year. This course is open to any individual interested in maxillofacial surgery. In this pre-symposium, attendees learn how the experts in craniofacial surgery manage basic and complex maxillofacial conditions.

As you can see, the ASMS provides a great number of excellent educational courses for its members and candidate members. Please don't forget to check the ASMS website ([www.maxface.org](http://www.maxface.org)) to check for upcoming educational courses.



### UPCOMING ASMS COURSES

ASMS Basic Course: February 17-19, 2012  
University of California, San Francisco, California

ASMS Course: Advances in Facial Restoration and Rejuvenation: March 31-April 1, 2012  
Louisiana State University Cadaver Lab, New Orleans, Louisiana

ASMS Basic Course: August 3-5, 2012  
Northwestern University, Chicago, Illinois

Plastic Surgery 2012: October 26-30, 2012  
New Orleans, Louisiana  
ASMS Pre-Symposium: Thursday, October 25, 2012  
ASMS Day: Sunday, October 28, 2012

ASMS Basic Course: January 18-19, 2013  
University of Miami, Miami, Florida

Challenges in Cleft Care in Underdeveloped Countries  
January 20, 2013, University of Miami, Miami, Florida



## ORBIT 2011 TEN YEARS LATER: *Ferrara, Italy October 13<sup>th</sup>-16<sup>th</sup>, 2011* Perspectives and Advances in Orbital, Cranio-Orbital Pathology & Surgery

**Luigi C. Clauser, MD, DMD, PhD, FEBOMS, Symposium Chairman**

The Congress ORBIT 2011 “Ten years later - Perspectives and Advances in Orbital, Cranio-Orbital Pathology & Surgery”, organised by Prof. Luigi C. Clauser, Director of the Cranio-Maxillofacial Surgical Department at S. Anna University Hospital, Ferrara, was held in Ferrara, Italy From 13th to 16th October.

The Co-Chairman of the Congress was Prof. Julio Acero, Education and Training Officer EACMFS, Director of the Department of Oral and Maxillofacial Surgery at the “Gregorio Marañón” University Hospital in Madrid, Spain.

The Congress was held under the auspices of three scientific societies: the SICMF (Società italiana di Chirurgia Maxillo Facciale- The Italian Society of Maxillofacial Surgery) the ASMS (*American Society of Maxillofacial Surgeons*) and the EACMFS (European Association for Cranio and Maxillo Facial Surgery) attended by their respective Presidents, Giuseppe Ferronato (SICMF), Robert Havlick (ASMS), and Miso Virag (EACMFS), and among the faculty there were 7 ASMS presidents, 4 SICMF Presidents and 4 EACMFS presidents.

The main topic of the meeting was orbit surgery. All aspects concerning this complex anatomical area, which involves various specialists, were covered.

Specific topics dealt with all eye diseases, from traumatology to oncology, from malformations to cosmetic surgery, and from endocrine orbitopathy to endoscopic surgery.

ORBIT2011 was dedicated to the memory of Paul Tessier, the father of Cranio- Maxillofacial Surgery.

This congress was held exactly ten years following the ORBIT2001 Congress held in Ferrara in 2001, when the guest of honour was Dr. Paul L. Tessier, himself, who gave his last public speech entitled “Craniofacial Surgery: the origins, principles, basic techniques and perspectives”.

Two particularly interesting parts shaped the meeting

and will be remembered for years to come. A mix of past, present and future history. The first one was the session devoted to Paul Tessier, the father of Cranio- Maxillofacial Surgery who passed away in 2008. Tribute to Tessier was made by all the surgeons who have the great fortune to have been his pupils and to have worked with him. Among these we recall Luigi Clauser - Ferrara, Bernard Devauchelle - Amiens, Darina Krastinova - Paris, Henry K. Kawamoto - Los Angeles, Joseph G. McCarthy - New York, Serge Morax - Paris, and S. Anthony Wolfe - Miami.

Madame Mireille Tessier honoured the meeting with her presence and, visibly touched by the images and remarks expressed by her husband's pupils, she intervened with a moving greeting. She was presented with a plaque in memory of her husband.

All the participants had the chance to see, perhaps for the last time, the work of the man who paved the way for present day surgeons; at times we take for granted some procedures or instruments that would not exist if it had not been for such an enlightened man as Tessier.

Another highly significant moment of great scientific value during the meeting was the session on Facial Transplantation, Bioethics and Tissue Engineering, with three of the world's leading surgeons who have carried out face transplants: Bernard Devauchelle, Amiens-France, Maria Siemionow Cleveland, USA, and Juan Barret Nerin, Madrid -Spain.

Their experience, which constitutes a moment of immense historical and scientific interest, gave us an invaluable insight into the current situation and future prospects of this highly intricate field, undoubtedly laying the foundations for new pathways in facial surgery. It is certainly not to be seen as a break from the past, but rather as one more step towards the resolution of particular cases that traditional surgery is unable to solve satisfactorily.

*(continued on next page)*



**ORBIT: Ten Years Later** *(continued from previous page)*

The faculty was composed of 65 invited speakers of International renown, coming from all corners of the globe, including 20 speakers from the USA.

The Congress was attended by over 400 delegates from 34 countries: Austria, Belgium, Bosnia, Bulgaria, Cyprus, Croatia, Czech Republic, Denmark, Egypt, Finland, France, Germany, Greece, Hungary, Israel, Italy, Kenya, Latvia, The Netherlands, Norway, Poland, Portugal, Qatar, Romania, Russia, Slovakia, Slovenia, Spain, Switzerland, Turkey, the UK, Ukraine, and the USA.


Similarly to ORBIT 2001, this event had the orbit as its main topic, covering all pathologies, diagnostics, surgical approaches and techniques, anatomy and physiology, imaging and simulation, new materials, aesthetic aspects and future prospects. The spectrum ranged from traditional surgery to the latest mini-invasive techniques.

The scientific level of each and every communication was of the utmost importance. Every discussion was characterised by an animated exchange of opinions, explanations and proposals for a very interesting future.

The Congress was not without its convivial moments, culminating in the get-together dinner in the Renaissance palace of the Duchess Isabella D’Este. This event provided an exceptional opportunity to meet and converse with the leading figures in our discipline, considered real icons, who up till now have represented to many merely names in books and on surgical instruments. For our young professionals, above all, the excitement of being able to exchange opinions with certain giants in the field will, undoubtedly, remain an unforgettable moment in their career. Before the Congress, a workshop was held in collaboration with Piezosurgery Medical on Ultrasound techniques Bone Surgery in Cranio Orbital Osteotomies, which constituted a valuable chance to learn more on ultrasound techniques in surgery from both the theoretical and practical points of view. The workshop

was a huge success, attended by a large number of surgeons - many young doctors at the outset of their careers, joined by some of the most illustrious members of the field, curious to see the advancements in this cutting-edge technique.





▶ **ASMS Advances in Facial Restoration and Rejuvenation**

May 12-13, 2012  
Louisiana State Cadaver Lab  
Louisiana State University, New Orleans, Louisiana

**A Word from the Chairmen**  
Thank you for your interest our inaugural ASMS/LSU program entitled Advances in Facial Restoration and Rejuvenation. We are proud to be part of this dynamic educational program jointly sponsored by the American Society of Maxillofacial Surgeons, and the Maxillofacial Surgeons Foundation. We hope you enjoy the program.  
Larry Hollier, MD | Henry Kawamoto, MD, DDS | Warren Schubert, MD

View Online Program

Housing

Download Course Brochure

Member Registration

Non-member Registration

Download Registration Form

This course is supported by an educational grant from Stryker.


stryker®



## Book Review: *Plastic Surgery: Clinical Problem Solving*

*Peter J. Taub and R. Michael Koch, Editors*

Review by Reza Jarrahy, MD



McGraw Hill Medical  
Publishers, 2009  
348 pages

*Disclosure: I am an author of one of the chapters of this text. While I receive no royalties from its publication, I did receive a complimentary copy of the initial printing.*

There are several criteria that should be met for a clinical review textbook on a particular medical or surgical specialty to be relevant. First, it should be comprehensive, covering all of the common presentations of disease that are pertinent to the area of focus. Second, it should provide concise but thorough summaries of the clinical entities being described, including background information, descriptions of the involved anatomy or physiology, and clinical context.

Third, these summaries should be provided by true voices of experience and authority. Fourth, the level of the educational content should be broadly applicable, so that students, trainees, and practitioners alike might benefit. Finally, and perhaps most importantly, a work such as this should be a truly usable resource, not a volume that sits on an overcrowded and underutilized library shelf.

Thankfully, Drs. Taub and Koch have provided us with just such a resource. In *Plastic Surgery: Clinical Problem Solving*, Taub and Koch have provided plastic surgeons, medical students, residents, and fellows a comprehensive and easily digestible volume that covers all of the major topics in plastic and reconstructive surgery.

The 348 page single volume text presents summaries of 52 of the most common clinical problems in plastic surgery, including cleft and craniofacial surgery, head and neck reconstruction, cosmetic surgery, pediatric plastic surgery, general reconstruction, and hand surgery. The format of the chapters is relatively unique, however, for a review text such as this. Each topic is introduced by a full-page color image of a particular clinical entity and a sentence describing the presenting clinical scenario, similar to how the “unknown” cases given to candidates sitting for the American Board of Plastic Surgery Oral Examination are introduced. What follows is a summary of the clinical entity presented first through a series of the most relevant questions that should be asked and answered when taking a history as well as the most pertinent physical exam findings associated with the diagnosis. Recommendations for diagnostic studies and relevant consultations to be obtained are made. Evidence-based treatment recommendations are made and relevant references are cited. Common complications and adverse

events associated with surgical intervention are discussed and practical clinical pearls are offered in many chapters. Finally, all of this information is concisely summarized at the end of each chapter in an easily referenced flow chart. Notably, the chapters are authored by widely recognized leaders in our field, including more senior and young innovative surgeons. The author list reads as a veritable “who’s who” of plastic and reconstructive surgery.

On the surface, this textbook seems to be targeted to plastic surgery residents and fellows who can use it to prepare for their cases, clinics, rounds, conferences, and in-service examinations. Medical students interested in plastic surgery will also find it a valuable resource to learn more about common clinical problems in a way that is accessible. In addition, it will serve as an invaluable resource to candidates sitting for the ABPS Oral Examination for certification. This group will certainly find the layout of the chapters very useful, as they present the summary information in a fashion that mirrors the oral exam format. Trainees, however, are not the only ones who will enjoy this reference. Practicing surgeons will be served by the thorough yet easily consumed summaries that are based on realistic clinical scenarios. In recent years we have seen a shift in plastic surgery practices, due in no small part due to our stagnating national economy, wherein surgeons are performing reconstructive procedures that may not have been part of their routine case

load. A text such as this is a perfect reference to turn to for quick and comprehensive reviews of topics that might not be immediately familiar. Moreover, the references provided can guide practitioners to additional helpful resources.

Drs. Taub and Koch are to be commended for taking a new spin on an old concept: they have taken the notion of a review textbook and edited a volume that is unique in its clinical focus on common presentations of common entities in plastic and reconstructive surgery. Its impressive author list and its concise style make it a truly relevant resource. My copy has yet to gather a speck of dust on my bookshelf.

---

***A text such as this is a perfect reference to turn to for quick and comprehensive reviews of topics that might not be immediately familiar. Moreover, the references provided can guide practitioners to additional helpful resources***

---

## Case Study: Reconstruction of a Medial Canthal, Orbital Floor, Maxillary Defect with Free Tissue Transfer and Bone Grafts

Christina N. Cordeiro, Peter G. Cordeiro, MD, FACS, New York, NY

### History

This patient is a 70 year old woman who presented with an invasive squamous cell carcinoma of the left nasal skin overlying the nasal bone and medial maxilla in 2007. She underwent a resection and reconstruction with a full thickness skin graft in early 2007. She developed a local recurrence two years later and presented with biopsy-proven recurrent invasive squamous cell carcinoma invading the nasal bone, medial orbit, anterior ethmoid sinus, maxillary sinus, and lacrimal system.

### Surgical Defect

The patient underwent resection of the skin surrounding a previous skin graft, soft tissue overlying the medial nasal wall and cheek, the inferomedial portion of the floor of the orbit, the anterior maxillary antrum, and a portion of the nasal bone.

### Considerations

This defect involved the anterior and medial walls of the maxilla as well as the soft tissue and skin overlying the defect. A portion of the lateral nasal wall and nasal lining was also resected. The critical structures that needed to be addressed were the lower eyelid, inferomedial wall of the maxilla, the orbit, as well as the soft tissues overlying the anterior maxilla. The reconstruction would need to provide support to the globe, resurface the cheek and the lining of the nasal cavity, and to fill in the soft tissue contour defect with well vascularized tissue. Prevention of ectropion and maintenance of the lower eyelid position was also essential.

### Operative Approach

An iliac crest bone graft was harvested from the medial cortex of the iliac crest. This was shaped to reconstruct the inferomedial wall of the orbit, and plated to the nasal bone superiorly and the floor of the orbit laterally. A radial forearm flap skin island was then utilized to provide soft tissue and skin to the cheek defect, and a second skin island folded over to reconstruct the lining of the nose. A tunnel was created from the defect to the neck. An end-to-end anastomosis was performed between the radial artery and the superior thyroid artery and an end-to-side anastomosis between the cephalic vein and the internal jugular vein. About 1/4 of the medial eyelid was deficient and in order to allow good closure, a lateral canthotomy and cantholysis was performed to allow the lid to move 1 cm medially. Canthopexies medially and laterally were then performed to maintain the eyelid in good position.

### Post-Operative Course

The patient did well post-operatively and maintained excellent eyelid position. Support to the globe post operatively also was achieved. She had no ectropion or vertical dystopia. She was happy with the overall cosmetic outcome, and did not wish any further revisions. She also underwent post-operative radiation therapy and did well.

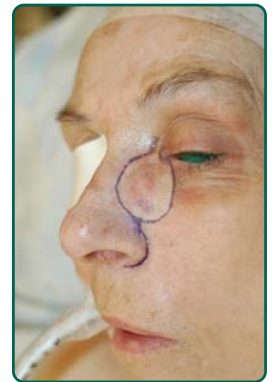

Figure 1: Preoperative design of skin and soft tissue excision.

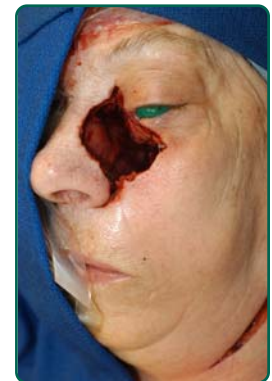

Figure 2: Defect of skin, medial lower eyelid and soft tissue. Bony defect involving medial and inferior wall floor of orbit, anterior maxilla.

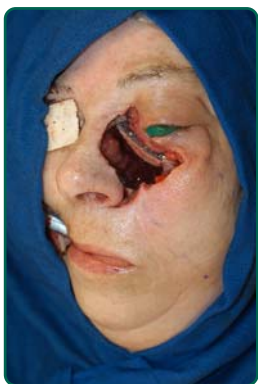

Figure 3: Iliac crest bone graft to floor of orbit rigidly fixed with titanium plates and screws.

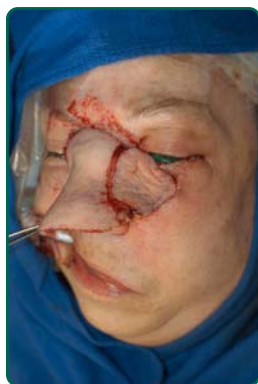

Figure 4: Two skin island radial forearm free flap prior to inset.

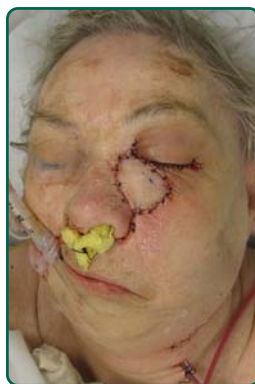

Figure 5: Skin island inset externally with second island inset to reconstruct lateral nasal wall.

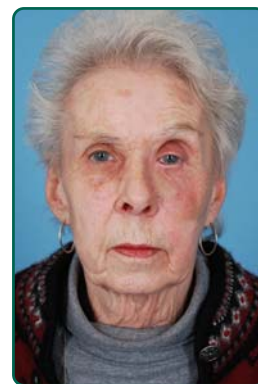

Figure 6: One year postoperative photograph after completion of adjuvant radiotherapy (front).

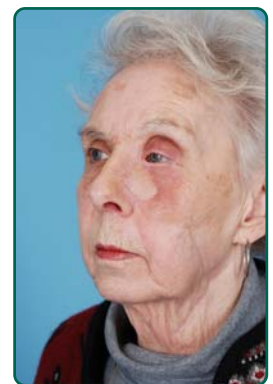

Figure 7: One year postoperative photograph after completion of adjuvant radiotherapy (side).

## CPT Coding: Orbital Floor Fractures

Gregory D. Pearson, MD



Although many orbital fractures are associated with zygomaticomaxillary fractures, isolated orbital fractures particularly orbital floor fractures have different codes depending upon the approach and reconstruction performed for repair. From a CPT coding perspective, orbital fractures are either classified as orbital floor fractures or “fracture of the orbit, except blowout.” This coding review will focus on isolated orbital floor fractures.

Orbital floor fractures have 5 CPT codes assigned to them (21385, 21386, 21387, 21390, 21395). **Code 21385** is defined as a trans-antral approach (Caldwell-Luc operation). A trans-antral approach involves a maxillary vestibular incision with creation of a bone window in the maxilla. The orbital floor is visualized via the sinus and the fracture is reduced via packing or ballooned catheter. Removal of the packing or balloon after proper healing is included as part of the global portion of this code.

**Code 21386**, open treatment of orbital floor fracture blowout; peri-orbital approach, involves making a skin incision (technically defined as a sub-tarsal incision), inspecting the floor, medial and lateral walls and the orbital rim. The floor is realigned and the fracture is stable or too small to require implant or bone graft. Closure of the skin in a layered manner is included in this code. Although this code technically defines a sub-tarsal incision, many surgeons prefer a transconjunctival approach. Closure of the transconjunctival incision should not be billed separately much the closure of the sub-tarsal incision is not. This code as good applicability for greenstick fractures in children with entrapment where the size of the defect is not typically large but reduction must occur.

**Code 21387**, open treatment of orbital floor fracture blowout; combined approach, involves both components of codes 21385 and 21386. In short, both a peri-orbital incision

and a gingivobuccal incision are made with resultant fracture reduction and maxillary packing. Like the previous codes, closure of the wounds and removal of the packing are bundled with this code.

Unlike the previous codes, code 21390 and 21395 are associated with either alloplastic or autogenous implants to repair the fracture. **Code 21390**, open treatment of orbital floor fracture blowout; peri-orbital approach with alloplastic or other implant, has the same procedural description as code 21386 regarding opening incisions, inspection and reduction. Bony fragments that are removed to assist with reduction or for exposure should not be coded as separate entities. A bony hole is found which must be fixed to prevent the orbital soft tissue from relapsing into the sinus below. An alloplastic implant is fashioned to cover the defect and secured in place. Like its predecessors, closure is included with this code.

**Code 21395**, open treatment of orbital floor fracture blowout; peri-orbital approach with bone graft, has an identical description to code 21390 except a bone graft is harvested from the hip, ribs, or skull. The obtaining of the bone graft including opening, anatomies and wound closure are included in the description associated with this cpt code and cannot be unbundled.

*From a CPT coding perspective, orbital fractures are either classified as orbital floor fractures or “fracture of the orbit, except blowout.”*

**THANK YOU to the following for their continued support of ASMS**



Douglas Ousterhout, MD

Operation Smile

David Genecov, MD, DDS

American Academy of Pediatrics

Carefusion

Lifecell



## ASMS President's Message *(continued from page 1)*

ence symposium was the largest that ASMS has enjoyed in recent memory. Furthermore, it continued a series of successful pre-conference symposia such that this event has gradually become a regular "fixture" in the plastic surgery program, and has truly developed into one of the highlights of the week. In the past, this program has been jointly administered by both ASPS and ASMS. For the first time, the 2012 pre-conference symposium in New Orleans will be led exclusively by ASMS. This new arrangement provides both opportunities and additional responsibilities for ASMS moving forward. Dr. Steve Buchman gave an outstanding talk on mentoring in plastic surgery, which was truly one of the highlights of the ASPS Opening Ceremonies, and indicative of the great job that Steve did as President of the Society. Dr. Vasconez also had a wonderful selection of papers on Saturday which highlighted the contributions of younger maxillofacial surgeons. ASMS day on Sunday featured Dr. Henry Kawamoto as the Kazanjian lecturer speaking on "Learning from the Masters", and panels on soft tissue defects of the face and scalp, innovative techniques in head and neck reconstruction, controversies in ear reconstruction, aesthetic refinements in secondary cleft surgery, and the surgical treatment of craniomaxillofacial pain. The programming provided by ASMS represented a prominent place within plastic surgery week, and all components were well attended.

The transition to PRRI, Inc. from ASPS went smoothly, thanks to extraordinary effort by both PRRI and ASPS. PRRI, Inc has a track record of excellence as association managers for plastic surgery groups, including both the Northeastern Society of Plastic Surgeons and the Southeastern Society of Plastic Surgeons. The ASMS administrative team, led by Stan and Aurelie Alger, were able to quickly ramp up to functional speed under the guidance and oversight of Dr. Steve Buchman, Past President of ASMS. This change in management companies has already begun to be beneficial. We have had enhanced clarity in accounting and financial reports, under the guidance of Treasurer Dr. Kant Lin, and we have also enjoyed a responsive management company that works very well with the Board of Trustees of ASMS. This enhanced clarity in accounting has provided us with the tools for critical assessment of our educational initiatives. With the transition behind us, we look forward to a great year with PRRI as our partner.

While ASMS has been primarily focused mainly upon the "Basic Course" and the Annual Meeting, our educational initiatives are much broader now. At the 2011 Denver meeting, the ASMS Education Committee met and outlined an ambitious agenda for the coming year. The Basic Course will be held in San Francisco in February and in Chicago in August. This core programming on the fundamentals of maxillofacial surgery has enjoyed very solid attendance

since the curriculum and formatting were revised 6-7 years ago. In addition, in May 2012, the ASMS will also provide a new course on **Advances in Facial Restoration and Rejuvenation** utilizing one of the finest cadaver surgery facilities, located at Louisiana State University. This course will be chaired by Dr. Hollier, Dr. Schubert, and Dr. Kawamoto and promises to be one of the best courses that we have ever offered.

In addition, ASMS will join the American Society of Craniofacial Surgery in providing a **new collaborative course designed for craniofacial surgery fellows**. This course will be held at Barrows Institute in Phoenix in August, and will focus on providing an initial orientation to craniofacial fellows in a "boot camp" type approach. The course will utilize both didactic instruction and "hands-on" technical instruction. In addition, it provides a great event for the new craniofacial fellows to meet and talk.

The ASMS is also active in developing an updated edition of Jim Ferraro's classic textbook "Fundamentals of Maxillofacial Surgery". In addition, a craniofacial surgical atlas is also in the development phase, and will soon progress to the writing and production phase. The ASMS Board is also integrally involved with the development of the Plastic Surgery Educational Network (PSEN) with ASPS, as well as with Dr. Mimis Cohen and Dr. Seth Thaller in the ongoing development of the Hyperguide. I welcome you all to visit the Society's new website at [www.maxface.org](http://www.maxface.org), both to update yourself on the many new initiatives of the Society, but also to see how this website has "morphed" recently into a significantly improved site both from the appearance and functionality standpoints.

The core of ASMS has always been education of both its members and others regarding maxillofacial surgery, and preserving and guiding plastic surgery's key role within the exciting field of facial restoration. The vitality of the Board and the members of the Society's Committees during the recent meeting in Denver was really awe inspiring. Maxillofacial surgeons dedicated to the Society and to *getting it done!* There were over twenty-five individual surgeons at the Education Committee alone, and the discourse was dazzling. Now that our palette of educational initiatives and offerings has been so dramatically enhanced, we must look forward to making plastic surgeons aware of our new offerings, and work toward having them join ASMS! The Board has approved several initiatives over the year to help make this step possible – including the development of on-line membership application submission, as well as reduced membership fees for the first two years of membership eligibility. This is your Society, and I welcome you in joining me to continue its recent successes and engage others for membership in this very special group of plastic surgeons!

**...in May 2012, the ASMS will also provide a new course on Advances in Facial Restoration and Rejuvenation utilizing one of the finest cadaver surgery facilities, located at Louisiana State University.**

## Panel Discussion: Innovative Techniques in Reconstruction *(continued from page 3)*

what we have planned the reconstructed facial skeleton to look like, such as with a “neo-maxilla” or “neo-mandible” that is reconstructed with a bony free flap, usually the fibula. In addition to these models, which can be used not only as a reference but to actually bend the titanium hardware on preoperatively, or intraoperatively by a second surgeon to save time, modeling companies can also use this technology to provide us with computer-generated cutting guides. They are basically a custom designed “mitre-box” that may be attached to the patient’s fibula during surgery and will serve as a guide for the saw used by the surgeon to perform the osteotomies at the appropriate lengths and angles to create the planned reconstruction. In other words, these cutting guides are the tools that are used to translate the virtual planning into reality intraoperatively.

**Dr. Robb:** At the present time, are you aware of many centers, either in the United States or internationally, that have made use of this technology for their mandible or mid-face reconstructions?

**Dr. Hanasono:** Yes, there has been a great deal of interest in this technology in many centers within the U.S. This technique is used by centers where free-flap bone reconstruction is infrequently performed in order to both shorten the operative time and to add an increased level of confidence in performing these complex free flap reconstruction. At the same time, virtual planning and medical modeling also seem to be employed by centers with a high volume reconstructive practice to assist in the more difficult cases.

**Dr. Robb:** Are you comparing the outcomes that you are achieving with this technology to the standard non-CAD techniques?

**Dr. Hanasono:** We looked at a series of 34 of our reconstructions performed with the aid of virtual planning and medical modeling and we compared them to a control group matched by defect and by flap reconstruction and found that on average, we were saving an hour and a half approximately surgical time with a single flap, which is the usual scenario for most osteocutaneous free flap surgeries. However, many of the cases that we use this for are the most complicated cases and we often perform double free flaps for these cases. We found a reduction in time, but this wasn’t statistically significant and we hypothesized that this is largely due to the complexities in those cases in which multiple teams are involved and multiple components of the surgery take place in an overlapping fashion. Even if the difference in double free flap cases was not statistically significant, we believe that there is still an advantage because it reduces the fatigue of the reconstructive

surgeon in the amount of time that they spent doing their part of the surgery as well as their confidence in the accuracy of the reconstruction.

**Dr. Skoracki:** We are actually in the midst of another study to look at that. We are looking the accuracy of the traditionally performed surgeries and the surgeries done with the use of these newer technologies by comparing postoperative CT scan data to preoperative CT scan data, which represents the patients’ original mandibular structure. The preliminary results look very good and it seems that we are more accurate when using these technologies.

**Dr. Robb:** How has your use of osseointegrated implants with bony reconstructions been influenced by this technology?

**Dr. Skoracki:** I think that is an interesting topic. There are some groups in Germany and Switzerland who are using this technology to actually place osseointegrated implants into the fibula before transplanting it to the head and neck. This just reinforces the degree of accuracy and predictability possible with this technology. There is a tremendous potential for this technology to be utilized for implant-supported dental rehabilitation. We have become more accurate with our osteotomies and thereby, it seems, have enabled our maxillofacial prosthodontists to place more osseointegrated implants now than we used to be able to for a given patient. At this point I do not have any data to back this up, and am basing this statement on the feedback that I am getting from our maxillofacial prosthodontists.

**Dr. Hanasono:** In a more conventional sense though, dentists and oral surgeons use the same models to plan placement of osseointegrated implants. In fact, they probably use this technology even more routinely than reconstructive surgeons do.

**Dr. Robb:** How does planned postoperative radiation therapy affect your use currently of osseointegrated implants?

**Dr. Skoracki:** We prefer to place them prior to radiation. We tend to be as aggressive about that approach as possible, and that will sometimes entail that we will place osseointegrated implants into the native mandible at the time of resection if that still is available just because the success rate with the osseointegrated implants is higher in the non-irradiated bone. It is not just the long-term retention of the implants in the bone but also other complications such as soft tissue dehiscences and infections that occur more frequently when placing implants into a radiated area. Having said all that, our maxillofacial prosthodontist group is reasonably aggressive with placement of implants, even in the radiated patient. They tend to use hypobaric oxygen protocols before and after implant placement. However our preference, if at all possible, is definitely to perform implant placement before radiation. With regard to placing implants into the fibula free flap, some centers have explored performing placement of osseointegrated implants at the time of the initial free flap reconstruction. This obviously requires a great degree of skill on the part of the reconstructive and dental surgeons placing the implants, both in terms of concern for damaging the flap and in appropriately positioning the osseointegrated implants which must be placed at the correct angle for them to still be usable. Our present strategy is to place them, when possible, at a second operation, after the initial free flap reconstruction but before radiation therapy begins.

***We are looking the accuracy of the traditionally performed surgeries and the surgeries done with the use of these newer technologies by comparing postoperative CT scan data to preoperative CT scan data, which represents the patients’ original mandibular structure.***



**-Roman Skoracki, MD**

*(continued on next page)*

## Panel Discussion: Innovative Techniques in Reconstruction *(continued from previous page)*

**Dr. Robb:** How is the technology of surgical navigation impacted your use of these other technologies and your overall outcomes?

**Dr. Skoracki:** Stereotactic navigation is a powerful tool, mostly for mid-face reconstruction, including orbital floor reconstruction with implants and grafts as well as mid-facial reconstruction, using the virtually planed and medical modeled osteocutaneous free flaps to accurately confirm the correct 3-dimensional position. With the available imaging data and CAD technology we are able to create a very accurate replacement of the mid-facial bony structures, but the difficulty of its exact placement remains, in that there are no real landmarks for docking. If, for example the construct is placed too far forward, you change the facial shape significantly and you lose the ability to utilize that over-protruding segment of bone to place osseointegrated implants. If placed too far inferiorly you encroach on the chewing surface and mouth opening of the patient. It is therefore important that placement is as accurate as possible and half a centimeter or more of displacement will certainly make a significant difference in that area. Stereotactic navigation facilitates this exact placement. Another advantage that the use of stereotactic navigation has afforded us, especially in the mid-face reconstruction, is that we are able to perform a given surgery through a much more limited exposure, essentially all transorally, and still place the construct accurately. This has helped tremendously in those patients that have previously been radiated. Reopening a prior lateral rhinotomy incision that has been radiated will lead to very significant nasal and facial distortion that is extremely difficult to correct. It may also result in fistulas. All this may be avoided by not reopening a radiated lateral

*...a number of craniofacial plating companies have partnered with medical modeling services who have software engineers that can help plan and create the models.*



**-Matthew Hanasono, MD**

rhinotomy incision which is often made possible by using stereotactic navigation in select patients.

**Dr. Robb:** How would you advise an individual reconstructive surgeon that is interested in looking more aggressively at starting to use these technologies?

**Dr. Hanasono:** I think that adopting the virtual planning in medical modeling today has become quite straightforward and simple. As Dr. Skoracki mentioned, a number of craniofacial plating companies have partnered with medical modeling services who have software engineers that can help plan and create the models. The experience of these engineers is now such that they have a very good understanding of the kind of reconstructions that we do, and because of the ability to create these models via web-based video conferences, virtual planning and medical modeling can be accomplished from anywhere in the world and is available to any center that performs reconstructive surgery.

**Dr. Robb:** What comments do you have about any future directions that you see this type of mandible and mid-face reconstruction taking?

**Dr. Skoracki:** Future directions include an overall improvement in the accuracy of imaging and available computing power. This would improve the quality and resolution of the data sets that we work with. More powerful computing options would be able to handle these higher definition images. This will also likely be mirrored in the advances in the resolution and fine detail in the three-dimensional printing technology. This evolution will continue to push this technology further forward and also present us with new indications that we may not even be considering at this time.

Another more immediate advance is the tremendous potential for designing more intricate, functional osteotomies, especially the docking osteotomies from the fibula to the native mandible. Whereas in the past we generally stuck with straight perpendicular cuts, we can now start to make these at different angulations, or even intricate, pre-designed tongue-in-groove type of arrangements where we can increase the bone to bone surface contact area and also immediately improve some of the stability that is afforded by the bone to bone contact itself.

Another area we are beginning to explore is to utilize robotic technology to translate this virtual plan that is created on the CAD platform to the actual patient by employing and programming an assembly-line type robot to assist in the operating room.

**Dr. Robb:** Well, on that note, I will ask Dr. Selber, what expanding indications in head and neck reconstruction have emerged so that the robotic technology now has potentially become an important tool?

**Dr. Selber:** Well, first, I think it is important to distinguish the kind of robot that Dr. Skoracki was just talking about from the kind of robot that I've been working with and will be discussing. The former type of robot, that would be able to interface with say a di-comm file and execute a virtual plan, as Dr. Skoracki suggested, is of the pre-programmed variety that is capable of autonomously completing a single task exactly the same way every time, tirelessly and repeatedly. This variety of robot has largely replaced human workers on assembly lines in many manufacturing industries.. The type of robot that is being used in surgery, exemplified by the DaVinci system, is a command-control system, or what engineers call a master-slave system. This prototypical command and control robot was conceived of and developed by NASA as the space arm. In the surgical application, an operator sits in a console and controls a patient's side-cart with three robotic arms and an endoscope. The movements of the patient-side cart correspond to and are controlled directly by the surgeon in real time using two hand operated mechanisms that reside within the operating console I have been using this robotic surgical platform for three distinct applications. One is transoral robotic reconstruction of the oropharynx, to avoid mandibulotomies and high dose radiation for the reconstruction of difficult to reach oropharyngeal defects.. Another is robotic microvascular surgery, and this approach can really be applied to any sub-specialty in which microsurgery is performed by taking advantage of the precision and optics of the robot. And finally, minimally invasive harvest of muscle flaps, eliminating the morbidity associated with long incisions typically required to har-

*(continued on next page)*



## Panel Discussion: Innovative Techniques in Reconstruction *(continued from previous page)*

vest these muscles. These three areas are all stand-alone applications that can be dealt with as separate topics.

**Dr. Robb:** What do you see as the most important challenges now in the use of robotics in reconstruction of the head and neck?

**Dr. Selber:** Well, from the perspective of TORS, which is the acronym the otolaryngologists came up with for Trans Oral Robotic Surgery, I think it's important to understand the history and evolution of this technique. The impetus for transoral robotic surgery was born from the fact that even small tumors were still requiring transmandibular, translabial approaches with lingual releases to provide adequate access for resection and reconstruction. The problem was that there is a high degree of morbidity associated with these types of exposures. At the same time clinicians and patients were growing dissatisfied with this commando surgical approach, a number of clinical studies were surfacing demonstrating the proven effectiveness of chemoradiation therapy for smaller tumors. The 1991 VA trial comes to mind. So the combination of these forces caused a pendulum swing away from ablative surgery and towards chemoradiation therapy. The unfortunate consequence of that, as we've observed over the last twenty years, is profound morbidity and mortality related to these non-surgical modalities. Many patients have become oropharyngeal cripples who cannot speak or swallow, and chronically aspirate. So, I think TORS found a sweet spot in between incredibly aggressive surgery and other equally morbid modalities. TORS has the benefit of local regional control without splitting the mandible or delivering high dose chemoradiation therapy. That's the context. Now the initial conception of transoral robotic surgery, as it was conceived of by Greg Weinstein and others, was that smaller tumors would be removed through the mouth using the surgical robot, and that because of the smaller resections, no reconstruction would be required. Well, as TORS gained popularity and the indications were pushed to larger tumors in more anatomically sensitive areas, it became necessary for plastic surgeons to get involved with this technology. This is where I saw the opportunity to engage in robotic reconstruction of the oropharynx. Now, I believe there is an evolving conception of TORS in which larger resections are possible and the trans-oral robotic resections can be combined with small pharyngotomies for the extirpation of tumors. This way resection and reconstruction of larger tumors can be performed and a mandibulotomy can still be avoided. In these situations, a reconstructive surgeon would have to possess the necessary robotic skill to perform transoral inseting of both local and distant flaps.

**Dr. Robb:** Can you describe your current robotic expansion in head and neck reconstruction beyond what you are describing for TORS?

**Dr. Selber:** Well, we began with TORS, using the robot in the mouth to inset flaps where access was challenging, but couldn't help notice that the robot was potentially useful in multiple other scenarios. One application, facilitated by the extreme precision and high resolution three dimensional optics, is in the performance of micro-vascular anastomoses. The robot is capable of 5:1 motion scaling, meaning that when you move your hand 5 cm in the console, the robotic instruments move 1 cm. It is also capable of 100% of tremor filtration. These precision enhancements naturally lend themselves to optimizing the performance of really small surgery. Of course, as microsurgeons, small surgery is of deep and particular interest to us. So, I think that as innovators, we have stumbled

upon a machine that was primarily designed for laparoscopic applications, and cross-trained it into something that can be used fairly deftly for micro applications in a number of subspecialties, including ours.

**Dr. Robb:** Are there other flap applications that you developed or are beginning to develop that will have application to head and neck reconstruction?

**Dr. Selber:** For me, the most exciting emerging application is minimally invasive muscle harvest. There are many situations in which we want to harvest a muscle without the skin. Unfortunately, these harvests still require a lengthy incision to access both the pedicle and the distant insertion or origin of the muscle. So, one of the applications I have recently introduced into my practice is harvesting the latissimus dorsi and rectus abdominis muscles, with in some cases, only a 3 cm incision and 2 to 3 additional port sites. These have a lot application in the head and neck, particularly in our practice where oncologic resections of the scalp frequently result in the absence of periosteum and calvarium, require cranioplasties, and will go on to require radiation. Large free muscle flaps with minimal donor sites are ideal for these complex defects. These flaps are useful in other settings as well: It should not go unmentioned that the robotically harvested LD is a very nice addition to the lower pole in implant based breast reconstruction in NAC sparing mastectomies where no additional skin is required. The pedicled rectus is useful in robotically performed pelvic exenteration to supply vascularized tissue in the pelvis with no laparotomy. And of course, extremity applications of both free muscle flaps are obvious, all with a minimal donor site footprint.

*...we have stumbled upon a machine that was primarily designed for laparoscopic applications, and cross-trained it into something that can be used fairly deftly for micro applications in a number of subspecialties, including ours.*



**-Jesse Selber, MD**

**Dr. Robb:** You've described a great multi-disciplinary approach working with our head and neck colleagues at Anderson. Can you describe what robotic utility is progressing outside of MD Anderson that you are aware of?

**Dr. Selber:** The TORS reconstructions that we've discussed are now cropping up in multiple other centers where the transoral resections are in established use. I know of at least 5 major academic centers within the continental United States that have adopted this reconstructive approach. What's really interesting, though, is that even though a brand new field, robotic reconstruction is already catching like wild fire. It started with the spark of TORS and has jumped fire gaps across multiple disciplines. For instance, the urologists are now performing vasectomy reversals,

*(continued on next page)*

## Panel Discussion: Innovative Techniques in Reconstruction

(continued from previous page)

or vasovasotomies, which are microsurgical robotic procedures. The GYN surgeons are now performing tubal reversals, which is a microsurgical procedure for that specialty. The orthopedic surgeons are performing brachial plexus surgery and nerve transfers with the robot, and thoracic surgeons are performing thoracic outlet surgery with delicate approaches to neurovascular structures through the axilla. Hepatobiliary surgeons are enhancing their resections with the ability to perform hepatic artery and hepatobiliary anastomoses in more and more challenging situations. It's only a matter of time until the neurosurgeons realize that they can view stereotactically synched CT images in 3D while they operate in the robotic console. As a testament to this spirit, RAMSES, or the Robotic Assisted Microsurgery and Endoscopic Surgery society, just had its first international meeting. This is a group of people from all corners of the globe, united by the belief that robotic surgery and microsurgery share a future together. It was an electrifying meeting and I'm sure we're going to be hearing a lot more about this.

**Dr. Robb:** Well, clearly robotic training labs or training centers are going to be important. What do you know about the availability of these kinds of training centers where robots are available in most medical centers?

**Dr. Selber:** Well, one of the major limitations to widespread proliferation of robotic surgery outside the field of urology, general surgery, and GYN, is training on the robot. In those specialties just mentioned, robotic training is formalized in the various curriculae. Unfortunately, for trainees not in those fields, robotic applications will require significant independent time in a robotic lab learning how to use the system, and safely apply it to reconstructive applications. This cannot be done with an operating room robot. It has to be done with a dedicated laboratory robot, which does not exist in every hospital system. They can be found in various locations around the world, and we are lucky enough to have one here at Hermann Hospital in the Texas Medical Center. Once a surgeon identifies and connects to one of these labs, a significant investment of personal time on the part of the surgeon will be required in order to initiate and establish any kind of robotic program. This is only one of several barriers that exist to a robotic program. Others include block time, robotic utilization, cost structure and credentialing.

**Dr. Robb:** How do you see plastic surgery and even the individual practitioner incorporating robotic expertise in the future?

**Dr. Selber:** Some of this goes to the last question. I think that what we are going to see is a combination of early adopters of existing applications, and thought leaders of new applications who are willing to invest the time required to become skilled on the current platform, and apply it in their practice. There will be a whole other group of surgeons who will be poised for the arrival of the next generation of technology in surgical robots. Luckily, for reasons of rapid increases in computing speed (MIPS) over the past 5 years, we are on the very steep part of the curve of robotic surgical technology. We will soon see smaller machines, better optics, more

tailor made systems, a greater variety of instrumentation, and augmented reality visual displays. It is important to understand that this is the first robot that we have ever had, and for the purposes of surgery, and it was produced to essentially replace laparoscopic instruments. So, this is not a machine that is particularly well suited towards plastic surgical applications. That being said, it has certain obvious attributes that make it extremely desirable for those of us who do really precise work.

That cannot be held back, and the momentum will only accelerate with better technology. So, I think as the next generation of robots comes out and more robots come out that are geared towards replacing the microscope rather than replacing the laparoscope, we will see many more plastic surgeons using the robot for precise high magnification applications.

**Dr. Robb:** Any further comments about the values of these different technologies that we have discussed in terms of advancing head and neck reconstruction?

**Dr. Skoracki:** I think this particularly is an exciting time that we kind of have a convergence of all of these different technologies, and it will be exciting to see what will happen over the next 10-15 years. I think we have an idea and we have a glimpse of what might happen but I think we will be surprised by the applications that will be discovered by some of the users. I think there

will be a very significant change in some of the areas that we practiced at this stage.

**Dr. Selber:** I think that one of the ways that we can combine applications that Dr. Hanasono and Dr. Skoracki have talked about with some of the ones that I have talked about is in the arena of improved work flow for virtual planning and medical modeling. For instance, if it's possible to upload DCOM files into the robotic software, that would allow guided execution of a virtual plan. The surgeon could then go right from the virtual plan to the surgery, without the medical model and all the cutting jigs, because these could be performed by a robot according to stereotactic landmarks. The virtual plan would be part of the robots instructions, so to speak. There will also be a substantial role for augmented reality in this setting. There exists the possibility to toggle back and forth between stereotactically synched CT images and the 3D camera, or have multiple tiles within your display that would allow you to benefit from different imaging modalities simultaneously (this already exists with TilePro software).. For instance, you could have a stereotactically synched bony CT view for virtual planning, the actual patient view for executing it, and an indocyanine perfusion view to evaluate the blood supply for the flap and surrounding tissue, all in the same screen, or be working back and forth among these screens. So, I think a lot of the technology that was discussed by Dr. Hanasono and Dr. Skoracki would be enhanced by the particular set of attributes possessed by surgical robots.

**Dr. Robb:** Are you seeing that in 3 dimensions on your screen?

**Dr. Selber:** Right, so the current robot has two cameras that merge images to convey a 3 dimensional view into the surgeon's con-

(continued on next page)

## Panel Discussion: Innovative Techniques in Reconstruction *(continued from previous page)*

sole, but you know, one of the things that we have been working on with multiple robotic companies is trying to get the optics better for plastic surgeons. The endoscope on the DaVinci system does not have ideal optics because of the limitations inherent to an endoscope. Magnification is about 10 to 14, but resolution is suboptimal, and the zoom is digital, not optical. It pales in comparison to the high definition optics of the operating microscope, and so we are trying to get this level of optics into a robotic platform. Once that occurs, it is really going to propel robotic microsurgical applications into the forefront of our specialty.

**Dr. Hanasono:** I think one other thing is that all of these technologies are easily foreseeable that they will all become more widespread. Even now more and more centers have a robot available and there is a tremendous enthusiasm in terms of creating models and performing surgery on the computer as the software be-

comes more accessible. I think the availability of doing your own reconstructions yourself expands. It is foreseeable that the printing technology will become extremely widespread. The cost of the printers which used to be prohibitive and really only available to large institutions is expected to come down to the point that households can afford them. Not only can surgeons use this planning model surgeries, but this opens the door for a virtually unlimited variety of patient's specific implants for both reconstructive and even aesthetic applications.

**Dr. Robb:** I think it is amazing how far we have come in a relatively short time as has been evidenced by our discussion. Indeed the future we face is very exciting. I want to thank Dr. Skoracki, Dr. Hanasono, and Dr. Selber for their kind participation in this teleconference for the ASMS newsletter.

## You know the benefits of ASMS Membership....

.....Now's the chance to pass it on!



ASMS membership provides numerous benefits including:

*Artists in Facial Restoration*

- ◆ Access to the latest information and technology in Maxillofacial and Craniofacial surgery
- ◆ Educational opportunities and peer recognition in the field of Maxillofacial and Craniofacial surgery
- ◆ Reduced registration fees for the annual meeting and other symposia
- ◆ Subscription to the ASMS newsletter, Maxillofacial News
- ◆ Research grant awards
- ◆ Access to the website "Members Only" section where you can view educational videos and more.

Over the next several months, the ASMS will be reaching out to non-members, asking them to consider joining the Society. And no one knows the benefits of membership, better than our current members. So we are asking you to help us recruit your colleagues. Watch your email for the invitation (left) and submit the name(s) of any of your colleagues who would benefit from belonging to the ASMS. Or you can send them now to [logrady@prri.com](mailto:logrady@prri.com).

Just let us know who they are and we will do the rest!





## From the Editor *(continued from page 2)*

palate with a team approach for many years. We have put together multidisciplinary groups who focus on one small thing (clefts) and who have elevated the care for patients who are born with this congenital difference. I believe we should place the same focus on HFM and organize people in teams or within existing teams who share the same interest in HFM... What I learned from my fellowship is that this can be done. It needs to be done. The key to success, I believe, is communication amongst team members and, above all, mutual respect."

### **Greg Pearson**

#### **2008 CRANIO Fellow, Ohio State University**

"The LeFort III versus the monobloc advancement was what I was hoping to figure out. I am not certain that there is a correct answer... The LeFort III appears to lengthen the nose more and can alter the dimensions of the orbital contents differently than a monobloc. The monobloc does address the frontal bar/bone much more significantly but with substantial risk of infection... I imagine like most things in medicine the surgery must be tailored to the patient and one mold does not fit all... I did not appreciate the future mentorship that I would gain when I initially visited these surgeons but have appreciated since my visits, as I have utilized their knowledge in some of my more complex cases. Due to the CRANIO fellowship, I have changed my practice, which will affect many patients in the future."

### **Ataf Hussain**

#### **2007 ASMS International Fellow, Chennai, India**

"In all my travels during the fellowship period I was received very kindly by not only the Surgeons I had arranged to visit, but many of their colleagues, fellows, residents, research personnel, secretaries, scrub nurses, office and hospital staff. I wish to especially thank Dr John Mulliken, Dr Christopher Forrest and Dr Arun Gosain for accepting me as a fellow and generously allowing me to observe all their work and taking time off to explain techniques and discussing cases with me. I am also grateful for their unstinted hospitality during my visit. I wish to reiterate that the fellowship has played a substantial part in improving the range and quality of my work over the last 3 months following the fellowship. I wish the ASMS/ASPS and their surgical sponsors will continue with it so that many more cranio-facial surgeons and their patients from many more parts of the world will be benefited."

In summary, there are few programs as rewarding as the Fellowship programs sponsored by the ASMS for young surgeons involved in pediatric and craniofacial surgery both in North America and throughout the world. We encourage those of you who are early in your careers, or who know deserving individuals who may share in the benefits shared by past participants in these programs, to continue to utilize these offerings of the ASMS to their fullest extent.

## PSEN wants YOU!

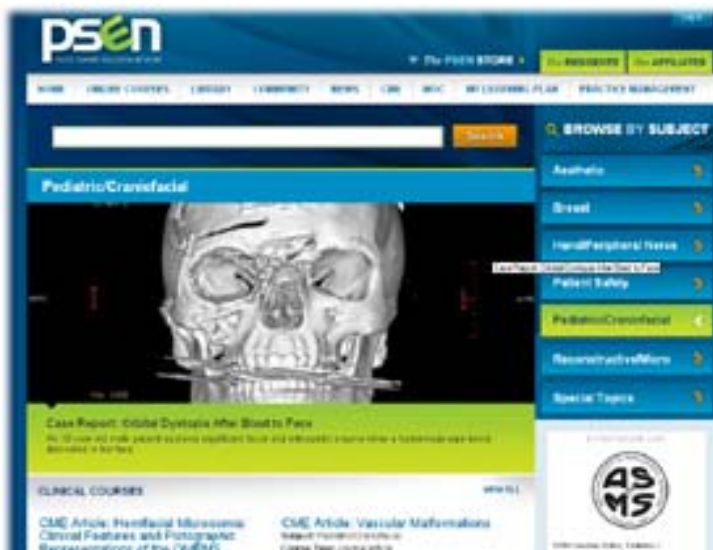The Plastic Surgery Education Network (PSEN) was designed to be a valuable tool for plastic surgeons in all arenas of practice. But for it to truly serve everyone, it needs broad participation. The more plastic surgeons use it, the faster and more useful it will become to all. The new site has a Community section, which allows plastic surgeons to pose questions and suggestions to each other on clinical topics at their leisure, which should make for a valuable "watering hole" for all clinicians. This is an area that all plastic surgeons can contribute to at any time. But plastic surgeons can also contribute to the site's other content areas.

The site's main content is managed by Section Editors for each distinct topic area

(Aesthetic, Breast, Hand/Peripheral Nerve, Patient Safety, Pediatric/Craniofacial,

Reconstructive/Microsurgery and Special Topics). And each Section Editor has solicited a team of assistant editors to bring in new, fresh content to the site every month, whether in the form of literature reviews, case reports or videos.

The more people who contribute case reports and videos, the richer the site will be for everyone. Plastic surgeons who are interested in working with the PSEN editorial team to contribute content either occasionally, or more regularly as an assistant editor, are encouraged to contact [online\\_education@plasticsurgery.org](mailto:online_education@plasticsurgery.org) and specify their areas of interest.



## Presidential Address in Denver *(continued from page 1)*

Our Website committee has performed stellar work to improve and reinvent our website to make it more relevant and more user friendly. If you have not visited it I encourage you to do so at [www.maxface.org](http://www.maxface.org). Our Education Committee has also continued to push the boundaries of innovation and instruction. In addition to our basic course which remains our brand, we have advanced the mantle of the ASMS by taking on two new and exciting projects. The first, is a cutting-edge course aimed at the practicing plastic surgeon that addresses Advances in Facial Restoration and Rejuvenation. This lab cadaver course will give participants a unique opportunity to have a talented faculty give personal instruction on the latest techniques while participants can actually attempt these procedures and use the products for themselves. In addition, we have entered an agreement in principle to join with the American Society of Craniofacial Surgery to co-sponsor and extend their summer course for Craniofacial Fellows with ideas and innovations which are sure to bring the course to the next level. Indeed, it is an exciting time for our organization, and I ask any and all of you that are interested, to come and join us as we move forward. There is plenty of room in our society for those that would like to contribute. The ASMS is accessible enough to allow meaningful efforts to make a real difference and impactful enough to make your contributions count.

It truly has been both an honor and a privilege to serve as the 65th President of the American Society of Maxillofacial Surgeons over this past year. I am humbled by the long list of eminent surgeons that have held this office before me such as Dr. Kazanjian our 3rd President and Dr. Reed Dingman our 6th president who, like myself, hailed from the University of Michigan where he started the Plastic Surgery Training Program. Dr. Kawamoto was our 44th president with whom I had the privilege of doing my fellowship and Dr. Manson was our 50th president who had taken an interest in me as a young surgeon and helped to shepherd along my career. In an ironic twist, Samuel Shatkin was our 31st president and his grandson Adam is now training with me in our plastic surgery program at Michigan with the desire to become a craniofacial surgeon.

These relationships between teacher and student, between mentor and mentee, and between colleagues link us to each other as well as to the next generation of our



specialty. These relationships help us to sew the fabric and build the tradition of fellowship and excellence that bind us together as a community of plastic surgeons. Winston Churchill once said “We make a living by what we get, we make a life by what we give”. I am sure that if you closely examine your life, there will inevitably be a figure that helped or guided you into being the person that you are today. Whether you are in academics or private practice, I think the opportunity to teach, advise and support those early in their training and careers are all around us if we make a point to seek them out.

The word ‘mentor’ originates from the Greek poet Homer, who, in the epic, “The Odyssey,” describes an old friend who guides young Telemachus, the son, in making his way through manhood and ultimately in search of lost his father, Odysseus.

Perhaps the same can be applied to mentorship, which guides us to understand the inheritance within us and the possibility of achieving our full potential in our chosen profession. A True mentor assists with important transitions and helps decipher the priorities for our lives.

The role of mentors are ubiquitous throughout history. Socrates was a mentor to Plato. Plato, in turn was both a teacher and a mentor to Aristotle. And Aristotle was the chief mentor to Alexander the Great.

One of my favorite quotes on the subject is by Sir Isaac Newton who made the realization that we have a debt of gratitude to pay to those that help guide us and to give both the respect and due credit to those that came before us. “If I could see further than others, it was because I stood on the shoulders of giants.”

Idly contemplate your life, and you’ll find an entire cast of players who are neither star roles nor simple cameo bits. Woven through our days on this planet are a variety of individuals who are not only vital to our development as a person but who also play roles that are recursive in nature. I contend that each of us lives the hero’s journey — not once but many times — and that each time we choose wisely we complete a level. There are some special people with whom we come into contact, share a portion of the ride, that help us on our journey and without whom we would not fulfill our destiny... Many of those special people are our mentors.

When you first are growing up our parents are our main mentors, not only guiding us but teaching us right from wrong.

---

***What wonderful blissful and innocent faith and trust they put in us as we toil to make the world see on the outside what we all know is the beautiful inside of each of their loving souls.***

---

*(continued on next page)*

## Presidential Address in Denver *(continued from previous page)*

Grandparents also serves as particularly wonderful mentors, slightly removed from the everyday aggravation of childrearing, they can provide a loving detached perspective and often can see both sides of most issues. Grandparents have the wealth of knowledge of having been both a child and a parent, and their counsel can provide a sanctioned refuge from the heat of battle as you are growing up.

Once a career path is chosen, it is the kindness of strangers, and the interest and benevolence of others that can make all the difference. Certainly in my case that was true, I was able to meet individuals who understood as Mark Van Doren once said that “The art of teaching is the art of assisting Discovery” People, in our specialty, who took joy in contributing to the success of another individual.

Peter Randall taught me about the magic of pediatric plastic surgery and the ability to change a child’s life. Dr. Randall loved his job and he stirred my spirit and personally wrote me to encourage me to pursue my interests.

Linton Whitaker who trained me as a plastic surgery resident at Penn, Was perhaps the best surgeon I knew at analyzing a face to discern what the underlying abnormalities were. His honest assessments, though sometimes painful taught me a key to successful outcomes. Dr. Whitaker genuinely taught me the value and the true gift of constructive criticism, and I am better for the fact that he cared enough to share that gift with me.

At UCLA, I had the privilege to meet and train with one of my most fascinating mentors. The inimitable Dr. Kawamoto. He loved his job, he loved to be a surgeon, and he loved craniofacial surgery. His enthusiasm was contagious and he infused in me a desire to be like him in so many ways.

He worked hard and played hard and was extraordinarily devoted to his fellows. He treated me like a colleague and challenged me constantly. There was little time for sleep, he would say, so catch it when you can! He continues to be a pillar of support and still follows my career closely.

Finally, there have probably been no greater guides on

our road to knowledge as surgeons than our patients. I truly feel privileged to have had the opportunity to work with them throughout the years. They have taught me humility. They have given me joy. They have brought tears to me eyes. And they have given me the confidence and courage to push the limits of reconstruction. What wonderful blissful and innocent faith and trust they put in us as we toil to make the world see on the outside what we all know is the beautiful inside of each of their loving souls.

Classically a mentor is an older and wiser trusted advisor. I cannot help but think, however, that these children have guided me. Surely providence has imbued their spirit to help us to become better surgeons. Surely the essence of these children embody a hero’s journey. And there could be no more special people to share that journey with than the patients I have had the privilege to treat.

Being a Plastic Surgeon in this great country of ours allows so many of us to truly live a charmed life. Each of us has the opportunity to pay our good fortune forward by finding the time and opportunity to mentor another. Finding that opportunity is empowering as it allows us to make a consequential difference in our own life and in another’s at the same time. Or in perhaps a much grander way as said by Gandhi: “Be the change you want to see in the world”

Finally, If you will indulge me an opportunity to thank those closest to me: All of the work I do takes time, precious time, and it is, of course, a zero sum game, the time I spend as the president of ASMS is given to me as a present by the most precious people in my life, my family. I could not have been luckier in life then to be blessed with the most understanding and loving wife and children, who, are in my thoughts even when I cannot be there to tuck them in.

I am truly honored to have had the opportunity to address all of you people, my valued colleagues, here tonight. To be able to celebrate and share this honor with my parents Nathan and Lillian Buchman, my wife Cindy and my four young children Lauren, Brevin, Ally, and Bradyn is a gift I will cherish for the rest of my life!

Thank you so much.



plastic  
surgery

THE MEETING

October 26 - 30, 2012  
New Orleans, LA





plastic surgery 11™

